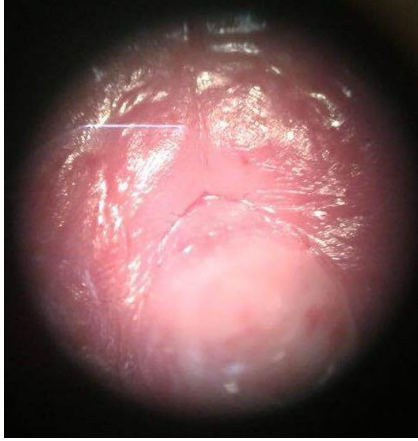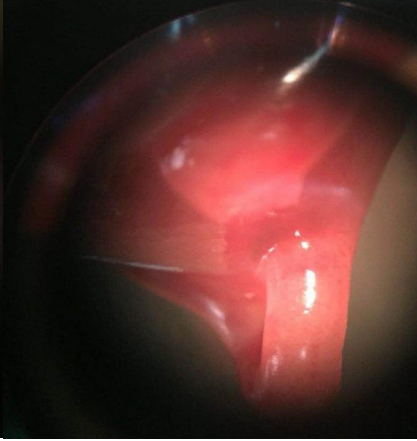


Supplymentary material 1

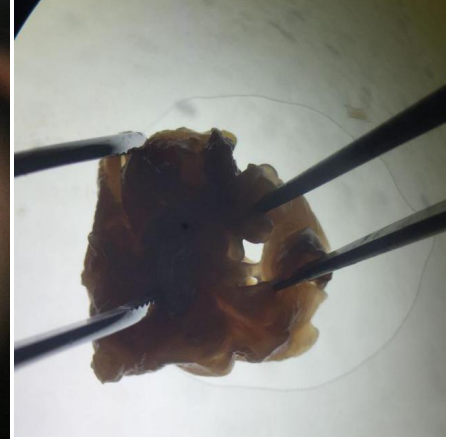
A



B



C



A The appearance of the anus of control E20 fetal rat under the stereomicroscope. **B** The appearance of the anus of ARM E20 fetal rat under the Stereomicroscope. **C** The hindgut tissue of fetal rats of E20