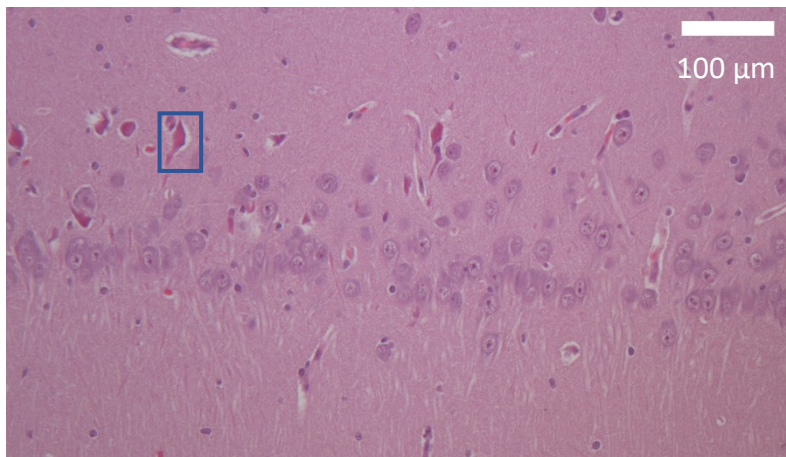
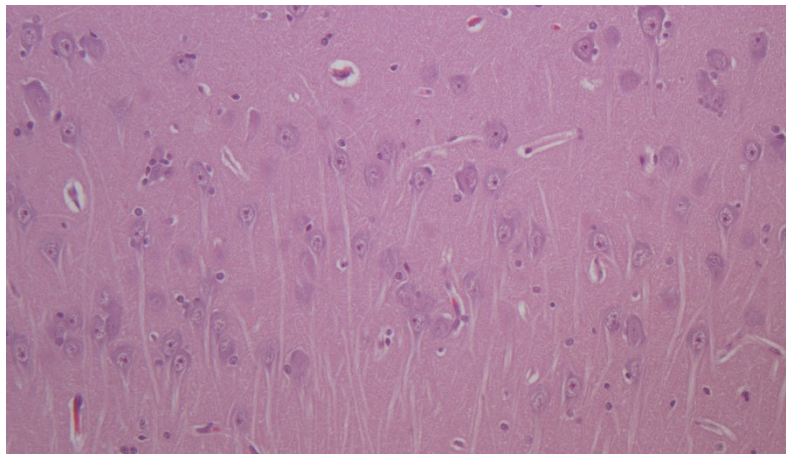


A



pyknosis and  
eosinophilic  
degeneration  
of a neuron

B



C

